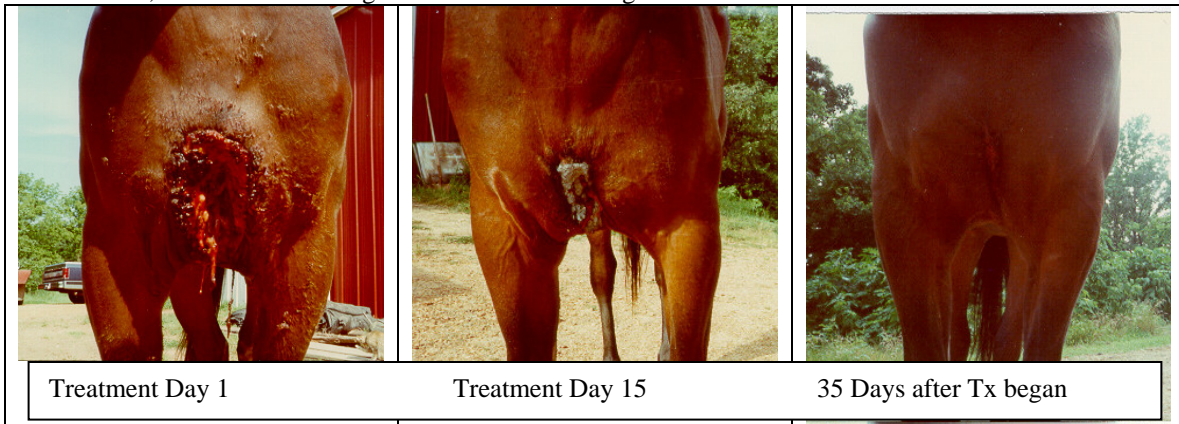

## Wound Healing Using the Respond Systems Lasers

Wound healing may be significantly improved by low level laser therapy. Even non-healing wounds can benefit, through the increased level of collagen brought about by laser treatment. Collagen, the chief constituent of connective tissue, is recognized as the most important ingredient in wound healing. See Dr. Andre F. Mester and Dr. Adam Mester, LLLT and Wound Healing, John Wiley and Sons, Ltd., 1989. A sample of the beneficial effects on wound healing is shown in this photo.

This quarterhorse mare was injured by running directly into a plastic pipe after breaking away from her trainer. The picture on the left shows a gaping hole with a large area of muscle and flesh torn from the greater sternum. This large open wound was the result, with the first picture being taken 7 days after the injury occurred. The recommendation was made to put the mare down. Instead, the owner decided to try using the laser to heal the wound, at the recommendation of David Cole. Penicillin was administered by the attending physician, and there were no sutures. The mare was lased twice daily for the first fifteen days of treatment, once in the morning and once in the evening.





The middle photo was taken on the fifteenth day of treatment. It evidences substantial healing, and impressive closure of the wound. From day 15 to day 35 the mare was treated once a day for about fifteen minutes per treatment.



The final photo on the left was taken just 35 days after treatment began. The only evidence remaining is an 8" scar about  $\frac{3}{4}$ " wide. Muscle tissue has regenerated and the mare is racing again.

Rick Chaffin, Ozark Mo. With a 8 YO Quarterhorse gelding Fetlock wound.

This is a very difficult area to heal because continual bending will open up the wound, delaying healing. The horse kicked through the side of a metal barn. After several weeks of conventional treatment, the wound was beginning to heal. At this time, the horse kicked through a mesh wire fence, hanging his leg and pulling all of the tissue down around the fetlock. Six weeks after the 2<sup>nd</sup> injury, with almost no healing taking place, the owners began laser therapy with the Respond 2400 Laser system.

|  |  |
|--|--|
|   |    |
| <p>The horse was lased twice daily for the first ten days at an F6 setting for about 5 minutes, concentrating on the swollen area of the leg and fetlock. After the first ten days, the horse was treated once a day for the remainder of the 6 week period. A small piece of proud flesh was removed from the wound in week four.</p> | <p>After six weeks of lasing, the horse is now totally sound, and is used as a hazing horse in steer wrestling! Another great example of how laser can help wounds to heal up quickly.</p> |

Another case of a tragic accident that could have resulted in the death of this calf, after it became entangled in barbed wire and tore large section of it's skin off. Due to the difficulty of roping the calf and treating it, it was only treated approximately 8 times over a 2 month period. This was a very deep wound, but after lasing over an 8 week period, the wound healed and hair grew back to a nearly normal condition.

|   |   |
|---|---|
|  |                                       |
| <p>Before we lased the calf the wound was very large and no doubt very painful.</p> | <p>After about 2 months of lasing, the hair is completely re-grown and this calf looks pretty happy to be well again.</p> |